



# Screening Examination of Premature Infants for Retinopathy of Prematurity

Section on Ophthalmology  
American Academy of Pediatrics  
American Academy of Ophthalmology  
American Association for Pediatric Ophthalmology and Strabismus

Organizational Principles to Guide and Define the Child Health Care System and/or Improve the Health of All Children

## ABSTRACT

This statement revises a previous statement on screening of preterm infants for retinopathy of prematurity (ROP) that was published in 2001. ROP is a pathologic process that occurs only in immature retinal tissue and can progress to a tractional retinal detachment, which can result in functional or complete blindness. Recent development of peripheral retinal ablative therapy using laser photocoagulation has resulted in the possibility of markedly decreasing the incidence of this poor visual outcome, but the sequential nature of ROP creates a requirement that at-risk preterm infants be examined at proper times to detect the changes of ROP before they become permanently destructive. This statement presents the attributes on which an effective program for detecting and treating ROP could be based, including the timing of initial examination and subsequent reexamination intervals.

## INTRODUCTION

Retinopathy of prematurity (ROP) is a disorder of the developing retina of low birth weight preterm infants that potentially leads to blindness in a small but significant percentage of those infants. In term infants, the retina is fully developed, and ROP cannot occur; however, in preterm infants, the development of the retina, which proceeds from the optic nerve head anteriorly during the course of gestation, is incomplete, with the extent of the immaturity of the retina depending mainly on the degree of prematurity at birth. The Multicenter Trial of Cryotherapy for Retinopathy of Prematurity demonstrated the efficacy of peripheral retinal cryotherapy (ie, cryoablation of the immature, unvascularized peripheral retina) in reducing unfavorable outcomes.<sup>1</sup> The study's 10-year follow-up report<sup>2</sup> confirmed these lasting benefits: unfavorable structural outcomes were reduced from 48% to 27%, and unfavorable visual outcomes (ie, best corrected visual acuity worse than 20/200) were reduced from 62% to 44%. Subsequently, laser photocoagulation has been used for peripheral retinal ablation with at least equal success.<sup>3-6</sup> Most recently, the Early Treatment for Retinopathy of Prematurity Randomized Trial confirmed the efficacy of treatment for severe ROP and redefined the indications for treatment.<sup>7</sup> Because of the sequential nature of ROP progression and the proven benefits of timely treatment in reducing the risk of

[www.pediatrics.org/cgi/doi/10.1542/peds.2005-2749](http://www.pediatrics.org/cgi/doi/10.1542/peds.2005-2749)

doi:10.1542/peds.2005-2749

All policy statements from the American Academy of Pediatrics automatically expire 5 years after publication unless reaffirmed, revised, or retired at or before that time.

### Key Words

retinopathy of prematurity, preterm infants

### Abbreviation

ROP—retinopathy of prematurity

PEDIATRICS (ISSN Numbers: Print, 0031-4005; Online, 1098-4275). Copyright © 2006 by the American Academy of Pediatrics

visual loss, effective care now requires that at-risk infants receive carefully timed retinal examinations by an ophthalmologist who is experienced in the examination of preterm infants for ROP and that all pediatricians who care for these at-risk preterm infants be aware of this timing.

This statement outlines the principles on which a program to detect ROP in infants at risk might be based. The goal of an effective screening program must be to identify the relatively few preterm infants who require treatment for ROP from among the much larger number of at-risk infants while minimizing the number of stressful examinations required for these sick infants. Any screening program designed to implement an evolving standard of care has inherent defects, such as overreferral or underreferral, and by its very nature cannot duplicate the precision and rigor of a scientifically based clinical trial. With that in mind and on the basis of information published thus far, the sponsoring organizations of this statement suggest the following guidelines for the United States. It is important to recognize that other world locations could have very different screening parameters.<sup>8</sup>

## RECOMMENDATIONS

1. Infants with a birth weight of less than 1500 g or gestational age of 32 weeks or less (as defined by the attending neonatologist) and selected infants with a birth weight between 1500 and 2000 g or gestational age of more than 32 weeks with an unstable clinical course, including those requiring cardiorespiratory support and who are believed by their attending pediatrician or neonatologist to be at high risk, should have retinal screening examinations performed after pupillary dilation using binocular indirect ophthalmoscopy to detect ROP. One examination is sufficient only if it unequivocally shows the retina to be fully vascularized in each eye. Effort should be made to minimize the discomfort and systemic effect of this examination by pretreatment of the eyes with a topical anesthetic agent such as proparacaine; consideration also may be given to the use of pacifiers, oral sucrose, etc.
2. Retinal examinations in preterm infants should be performed by an ophthalmologist who has sufficient knowledge and experience to enable accurate identification of the location and sequential retinal changes of ROP. "The International Classification of Retinopathy of Prematurity Revisited"<sup>9</sup> should be used to classify, diagram, and record these retinal findings at the time of examination.
3. The initiation of acute-phase ROP screening should be based on the infant's age. The onset of serious ROP correlates better with postmenstrual age (gestational

age at birth plus chronologic age) than with postnatal age.<sup>10</sup> That is, the youngest infants at birth take the longest time to develop serious ROP. This knowledge has been used previously in conducting a screening schedule.<sup>11,12</sup> Table 1 was developed from an evidence-based analysis of the Multicenter Trial of Cryotherapy for Retinopathy of Prematurity natural history data and confirmed by the Light Reduction in ROP Study, which was conducted a decade later.<sup>13</sup> It represents a suggested schedule for the timing of the initial eye examinations based on postmenstrual age and chronologic (postnatal) age to detect ROP before it becomes severe enough to result in retinal detachment while minimizing the number of potentially traumatic examinations.<sup>14</sup> Table 1 provides a schedule for detecting ROP potentially damaging to the retina with 99% confidence.

4. Follow-up examinations should be recommended by the examining ophthalmologist on the basis of retinal findings classified according to the international classification.<sup>9</sup> The following schedule is suggested (see Fig 1):

1-week or less follow-up

- stage 1 or 2 ROP: zone I
- stage 3 ROP: zone II

1- to 2-week follow-up

- immature vascularization: zone I—no ROP
- stage 2 ROP: zone II
- regressing ROP: zone I

2-week follow-up

- stage 1 ROP: zone II

**TABLE 1** Timing of First Eye Examination Based on Gestational Age at Birth

Gestational Age at Birth, wk	Age at Initial Examination, wk	
	Postmenstrual	Chronologic
22 <sup>a</sup>	31	9
23 <sup>a</sup>	31	8
24	31	7
25	31	6
26	31	5
27	31	4
28	32	4
29	33	4
30	34	4
31 <sup>b</sup>	35	4
32 <sup>b</sup>	36	4

Shown is a schedule for detecting prethreshold ROP with 99% confidence, usually well before any required treatment.

<sup>a</sup> This guideline should be considered tentative rather than evidence-based for infants with a gestational age of 22 to 23 weeks because of the small number of survivors in these gestational-age categories.

<sup>b</sup> If necessary.

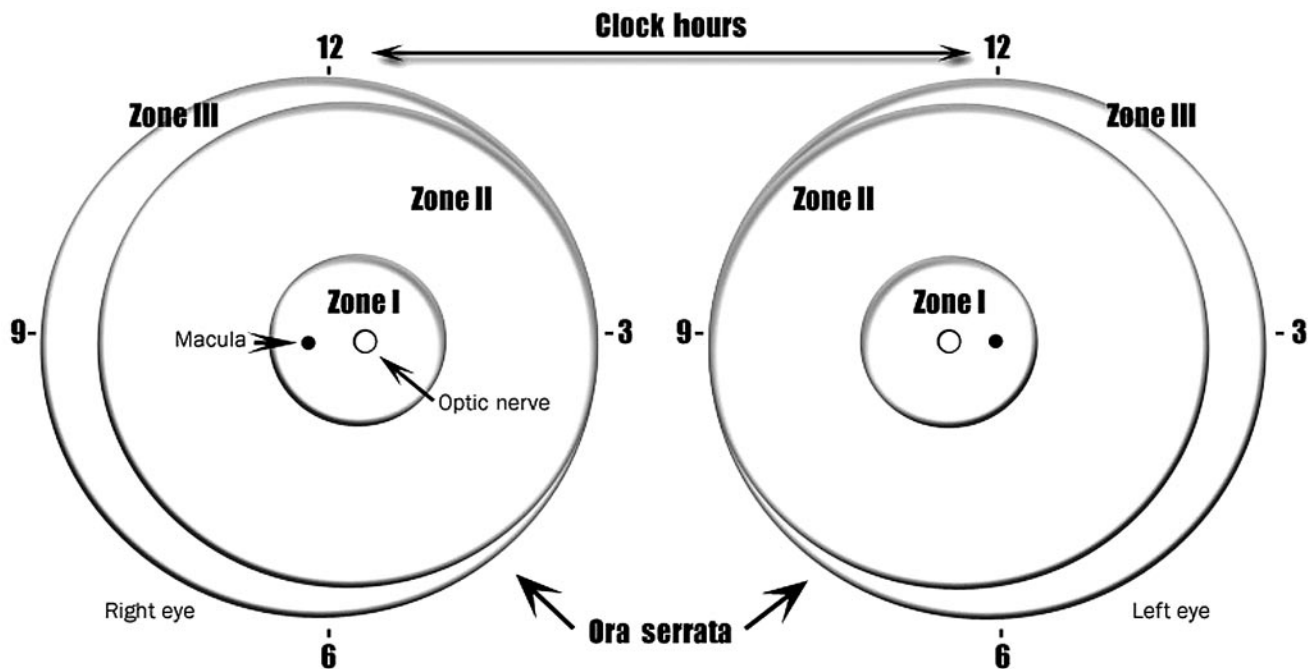


FIGURE 1

Scheme of retina of the right and left eyes showing zone borders and clock hours used to describe the location and extent of retinopathy of prematurity. Diagrammatic representation of the potential total area of the premature retina, with zone I (the most posterior) symmetrically surrounding the optic nerve head (the earliest to develop). A larger retinal area is present temporally (laterally) than nasally (medially) (zone III). Only zones I and II are present nasally. The retinal changes discussed in recommendation 4 are usually recorded on a diagram such as this.

- regressing ROP: zone II
- 2- to 3-week follow-up
- immature vascularization: zone II—no ROP
- stage 1 or 2 ROP: zone III
- regressing ROP: zone III

The presence of plus disease (defined as dilation and tortuosity of the posterior retinal blood vessels, see below) in zones I or II suggests that peripheral ablation, rather than observation, is appropriate.<sup>14</sup>

5. Practitioners involved in the ophthalmologic care of preterm infants should be aware that the retinal findings that require strong consideration of ablative treatment were revised recently according to the Early Treatment for Retinopathy of Prematurity Randomized Trial study.<sup>7</sup> The finding of threshold ROP, as defined in the Multicenter Trial of Cryotherapy for Retinopathy of Prematurity, may no longer be the preferred time of intervention.

Treatment may also be initiated for the following retinal findings:

- zone I ROP: any stage with plus disease
- zone I ROP: stage 3—no plus disease
- zone II: stage 2 or 3 with plus disease

Plus disease is defined as a degree of dilation and tortuosity of the posterior retinal blood vessels as defined by a standard photograph.<sup>1,9</sup> Special care must be used in determining the zone of disease. The number of clock hours of disease may no longer be the determining factor in recommending ablative treatment. Treatment should generally be accomplished, when possible, within 72 hours of determination of treatable disease to minimize the risk of retinal detachment.

6. The conclusion of acute retinal screening examinations should be based on age and retinal ophthalmoscopic findings.<sup>14</sup> Findings that suggest that examinations can be curtailed include the following:
  - zone III retinal vascularization attained without previous zone I or II ROP (if there is examiner doubt about the zone or if the postmenstrual age is less than 35 weeks, confirmatory examinations may be warranted);
  - full retinal vascularization;
  - postmenstrual age of 45 weeks and no prethreshold disease (defined as stage 3 ROP in zone II, any ROP in zone I) or worse ROP is present; or
  - regression of ROP<sup>15</sup> (care must be taken to be sure that there is no abnormal vascular tissue present that is capable of reactivation and progression).

7. Communication with the parents by members of the staff is very important. Parents should be aware of ROP examinations and should be informed if their child has ROP, with subsequent updates on ROP progression. The possible consequences of serious ROP should be discussed at the time that a significant risk of poor visual outcome develops. Documentation of such conversations with parents in the nurse or physician notes is highly recommended.
8. Responsibility for examination and follow-up of infants at risk of ROP must be carefully defined by each NICU. Unit-specific criteria with respect to birth weight and gestational age for examination for ROP should be established for each NICU by consultation and agreement between neonatology and ophthalmology services. These criteria should be recorded and should automatically trigger ophthalmologic examinations. If hospital discharge or transfer to another neonatal unit or hospital is contemplated before retinal maturation into zone III has taken place or if the infant has been treated by ablation for ROP and is not yet fully healed, the availability of appropriate follow-up ophthalmologic examination must be ensured, and specific arrangement for that examination must be made before such discharge or transfer occurs. The transferring primary physician, after communication with the examining ophthalmologist, should have the responsibility for communicating what eye examinations are needed and their required timing to the infant's new primary physician. The new primary physician should ascertain the current ocular examination status of the infant from the record and through communication with the transferring physician so that any necessary examinations by an ophthalmologist with ongoing experience and expertise in examination of preterm infants for ROP can be arranged promptly at the receiving facility or on an outpatient basis if discharge is contemplated before the need for continued examination has ceased, as outlined in recommendation 6. If responsibility for arranging follow-up ophthalmologic care after discharge is delegated to the parents, they should be made to understand the potential for severe visual loss, including blindness; that there is a critical time window to be met if treatment is to be successful; and that timely follow-up examination is essential to successful treatment. This information preferably should be communicated both verbally and in writing. If such arrangements for communication and follow-up after transfer or discharge cannot be made, the infant should not be transferred or discharged until appropriate follow-up examination can be arranged by the unit that is discharging the infant.

Pediatricians and other practitioners who care for infants who have had ROP, regardless of whether they require treatment, should be aware that these infants may be at risk of other seemingly unrelated visual disorders such as strabismus, amblyopia, cataract, etc. Ophthalmologic follow-up for these potential problems after discharge from the NICU is indicated.

This statement replaces the previous statement on ROP from the American Academy of Pediatrics, American Association for Pediatric Ophthalmology and Strabismus, and American Academy of Ophthalmology<sup>16</sup>; is evolving; and may be modified as additional ROP risk factors, treatments, and long-term outcomes are known.

**AMERICAN ACADEMY OF PEDIATRICS SECTION ON OPHTHALMOLOGY, 2003–2004**

Steven J. Lichtenstein, MD, Chairperson  
 Edward G. Buckley, MD  
 George S. Ellis, MD  
 Jane D. Kivlin, MD  
 Gregg T. Lueder, MD  
 James B. Ruben, MD  
 Gary T. Denslow, MD, Immediate Past Chairperson

**LIAISONS**

Michael R. Redmond, MD  
 American Academy of Ophthalmology  
 Michael X. Repka, MD  
 American Association of Pediatric Ophthalmology and Strabismus

**STAFF**

S. Niccole Alexander, MPP

**SUBCOMMITTEE ON RETINOPATHY OF PREMATURETY, 2003–2005**

\*Walter M. Fierson, MD, Chairperson  
 John Flynn, MD  
 William Good, MD  
 Dale L. Phelps, MD  
 James Reynolds, MD  
 Richard Saunders, MD

**AMERICAN ASSOCIATION FOR PEDIATRIC OPHTHALMOLOGY AND STRABISMUS**

American Academy of Ophthalmology

\*Lead author

**REFERENCES**

1. Cryotherapy for Retinopathy of Prematurity Cooperative Group. Multicenter trial of cryotherapy for retinopathy of prematurity: preliminary results. *Arch Ophthalmol.* 1988;106:471–479
2. Cryotherapy for Retinopathy of Prematurity Cooperative Group. Multicenter trial of cryotherapy for retinopathy of prematurity: ophthalmological outcomes at 10 years. *Arch Ophthalmol.* 2001;119:1110–1118
3. McNamara JA, Tasman W, Brown GC, Federman JL. Laser

- photocoagulation for stage 3+ retinopathy of prematurity. *Ophthalmology*. 1991;98:576–580
4. Hunter DG, Repka MX. Diode laser photocoagulation for threshold retinopathy of prematurity: a randomized study. *Ophthalmology*. 1993;100:238–244
  5. Laser ROP Study Group. Laser therapy for retinopathy of prematurity. *Arch Ophthalmol*. 1994;112:154–156
  6. Iverson DA, Trese MT, Orgel IK, Williams GA. Laser photocoagulation for threshold retinopathy of prematurity. *Arch Ophthalmol*. 1991;109:1342–1343
  7. Early Treatment for Retinopathy of Prematurity Cooperative Group. Revised indications for the treatment of retinopathy of prematurity: results of the early treatment for retinopathy of prematurity randomized trial. *Arch Ophthalmol*. 2003;121:1684–1694
  8. Phan HM, Nguyen PN, Reynolds JD. Incidence and severity of retinopathy of prematurity in Vietnam, a developing middle-income country. *J Pediatr Ophthalmol Strabismus*. 2003;40:208–212
  9. International Committee for the Classification of Retinopathy of Prematurity. The International Classification of Retinopathy of Prematurity revisited. *Arch Ophthalmol*. 2005;123:991–999
  10. Palmer EA, Flynn JT, Hardy RJ, et al. Incidence and early course of retinopathy of prematurity. *Ophthalmology*. 1991;98:1628–1640
  11. LIGHT-ROP Cooperative Group. The design of the multicenter study of light reduction in retinopathy of prematurity (LIGHT-ROP). *J Pediatr Ophthalmol Strabismus*. 1999;36:257–263
  12. Hutchinson AK, Saunders RA, O’Neil JW, Lovering A, Wilson ME. Timing of initial screening examination in retinopathy of prematurity. *Arch Ophthalmol*. 1998;116:608–612
  13. Reynolds JD, Hardy RJ, Kennedy KA, Spencer R, van Heuven WA, Fielder AR. Lack of efficacy of light reduction in preventing retinopathy of prematurity. Light Reduction in Retinopathy of Prematurity (LIGHT-ROP) Cooperative Group. *N Engl J Med*. 1998;338:1572–1576
  14. Reynolds JD, Dobson V, Quinn GE, et al. Evidence-based screening criteria for retinopathy of prematurity: natural history data from the CRYO-ROP and LIGHT-ROP studies. *Arch Ophthalmol*. 2002;120:1470–1476
  15. Repka MX, Palmer EA, Tung B. Involution of retinopathy of prematurity. Cryotherapy for Retinopathy of Prematurity Cooperative Group. *Arch Ophthalmol*. 2000;118:645–659
  16. American Academy of Pediatrics, Section on Ophthalmology. Screening examination of premature infants for retinopathy of prematurity. *Pediatrics*. 2001;108:809–811